

Clinical Image

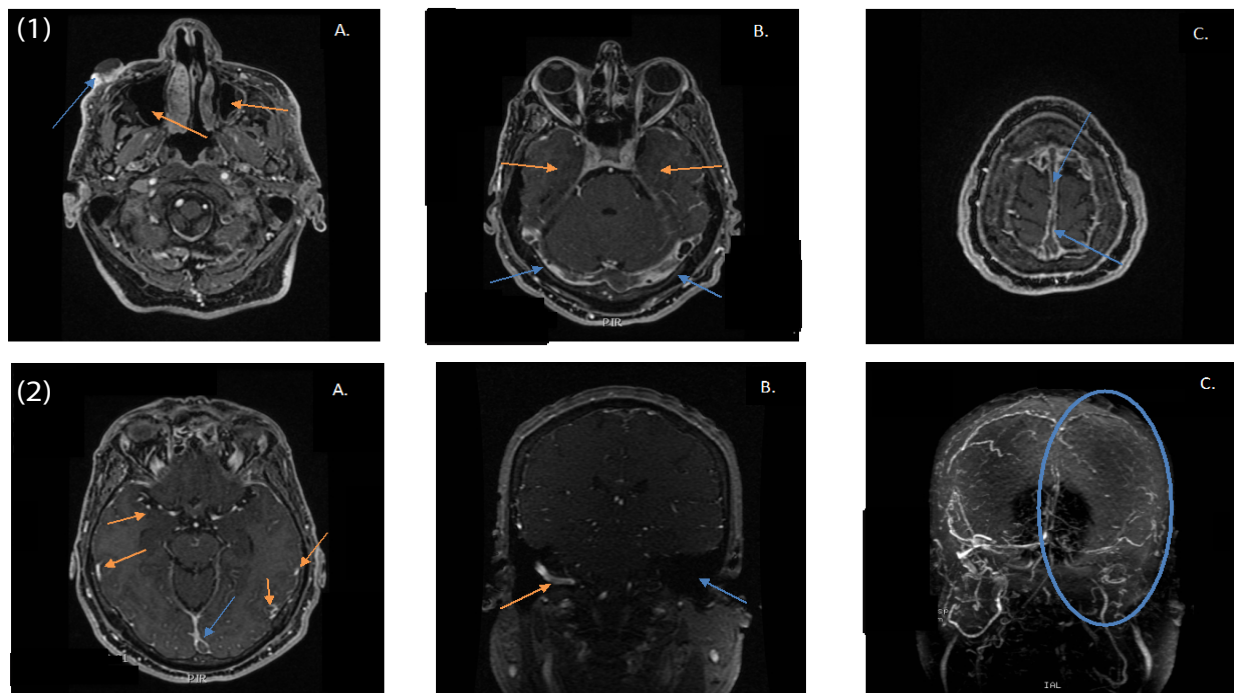
## A Massive Cerebral Venous Thrombosis Secondary to Facial Cutaneous Coccidioidomycosis Lesion: A Rare Pattern Presentation

Patrick Francois Tarquino<sup>1</sup>, John Elkin Pedraza<sup>2</sup> and Juan S Barajas Gamboa<sup>3\*</sup>

<sup>1</sup>Universidad del Rosario, Department of Medicine, Bogotá DC, Colombia, USA

<sup>2</sup>Universidad Pontificia Javeriana, Department of Medicine, Bogotá DC, Colombia, USA

<sup>3</sup>Universidad Autónoma de Bucaramanga, Department of Surgery, Bucaramanga, Colombia, USA



**Figure 1:** Cerebral MRI Angiography. A, B, C, and show a T2 weighted axial image at different levels showing extended cerebral venous thrombosis. A) Primary skin lesion of coccidioidomycosis in the right cheek (Blue arrow) also image shows bilateral maxillar and paranasal sinuses compromise (Orange arrows). B) Image shows bilateral transverse sinuses thrombosed (blue arrows) also shows bilateral hypodensity in the insular cortex (Orange arrows) C) Image shows complete compromised of the longitudinal sinus.

**Figure 2:** Cerebral MRI Angiography. A). Image shows a compromised longitudinal venous sinus (Blue arrow) and pial veins dilated secondary to cerebral hypertension (Orange arrows) B) MRI Enhanced Venography in coronal reconstruction shows absence of enhancement of left internal jugular vein (Blue arrow) and normal right intern jugular vein (Orange arrow). C) 3D reconstruction shows important disturbance of venous blood flow in the left side of the head (Blue ellipse) image also shows compromised of left internal jugular vein, left sigmoidal, bilateral transverse, straight. Partially compromise of torcula and longitudinal venous sinuses.

## Clinical Image

### Introduction

A 58 year-old male patient natural and resident of Duitama-Boyaca, Colombia, currently working at a local brewery with history of recent dermatological evaluation secondary to the present of a nodular plate of 2 × 2 cm, rough surface and irregular edges, warty aspect, associated with mild pain without bleeding. At this time, other symptoms referred by the patient included weight loss (4 kilograms), frontal tension-type headache with intensity 6/10 in the Visual Analog Scale (VAS) and dizziness during the last three weeks, with neurological focalization. Due to this, the patient was brought to the emergency room for medical assessment. In the physical examination a lesion is found specifically in the right zygomatic region and preliminary skin biopsy had revealed a fungal skin infection.

\*Corresponding author: Juan S Barajas-Gamboa, MD, Universidad Autónoma de Bucaramanga, Departamento de Cirugía, Bucaramanga, Colombia, USA Tel: 1 858-246-1004; E-mail: jbarajasgamboa@gmail.com

Citation: Tarquino PF, Pedraza JE, Gamboa JSB (2017) A Massive Cerebral Venous Thrombosis Secondary to Facial Cutaneous Coccidioidomycosis Lesion: A Rare Pattern Presentation. *Int J Clin Med Imaging* 4: 547. doi:10.4172/2376-0249.1000547

Copyright: © 2017 Tarquino PF, et al. This is an open-access article distributed under the terms of the Creative Commons Attribution License, which permits unrestricted use, distribution, and reproduction in any medium, provided the original author and source are credited.

As a result of the neurological symptoms, a Magnetic Resonance Image (MRI) of the brain was requested by the emergency physician due to the headache. Images showed an extended cerebral venous thrombosis including the superior sagittal, transverse, left sigmoid sinuses and ipsilateral internal jugular vein. Another finding comprised increased size of the cortical veins in the convexity and leptomeningeal enhancement after contrast administration.

For academic, research and publication purposes, an informed consent were obtained .The radiological findings and differential diagnosed are briefly discussed.

**Keywords:** Skin lesion; Thrombosis; Coccidioidomycosis; Fungus biology; Vascular biology

## Clinical Scenario

A previously healthy 58 year-old male with no relevant medical history presented with nodular plate of 2 × 2 cm, rough surface and irregular edges, warty aspect, without bleeding in the right zygomatic region, associated with frontal tension-type headache with intensity 6/10 in the VAS and dizziness.

CT scan of the brain had been performed routinely three months before showing radiological changes suggesting right maxilar sinusitis, with no other relevant changes. Laboratory tests taken in the emergency department in this patient, Complete Blood Count (CBC) and C- Reactive Protein (CRP) suggested an active infection process, and 12 hours after the initial admission the neurological status had changed with focalization and altered mental status; due to this change, physician request a cerebral MRI angiography which shows extended cerebral sinus thrombosis with related, leptomeningeal enhancement and cortical veins dilated after contrast administration, supporting the headache and altered mental status, image also described the same right maxilar sinusitis (Figures 1 and 2).Consequently, a lumbar puncture was performed confirmed positive fungal infection on the nervous system. Pathology reports of the skin biopsy showed a coccidioides immitis.

Top differential diagnoses coccidioidomycosis

1. Histoplasmosis
2. Blastomycosis
3. Criptococcosis
4. Candidiasis

Top differential diagnoses of dural venous sinuses thrombosis

1. Dural sinus hypoplasia
2. Giant arachnoid granulations
3. Acute subdural hematoma
4. High hematocrit levels

Infections caused by dimorphic fungi that compromise central nervous system appear with relatively low frequency in our environment. They are commonly found in patients with certain grade of immunocompromised, these subjects are at risk to acquire a leptomeningeal infection by any of its common pathways. The tropism presented by the fungi to the central nervous system is mostly unknown and even more difficult to suspect because most of the images do not show pathognomonic findings that allow us to classify the clinical signs and symptoms. Due to this reason, the diagnosis will always be considered and analyzed running clinical laboratory tests such as cultures and genetic engineering tests such as PCR, in combination with a complete physical examination in order to achieve an appropriate diagnosis.

Coccidioides immitis/posadassi infection has imaging findings which are intimately accompanying to the evolution of the infection, the clinical condition of the patient and their immunological status. Also infection stages are not clearly described; usually occurs in the context of meningitis: T2 weighted images in MRI demonstrate hyperintense enlargement at the leptomeningeal space with homogeneous enhancement becoming more visible after contrast administration. Then, the presence of meningeal edema generates hypertension of the cerebral venous vessels, which are engorged by compressing the meninges, a phenomenon that favors venous stasis and associated with the release of inflammation factors, which conducts to a venous sinus thrombosis, images such as those observed in this case. Additionally within the cerebral parenchyma, coccidioidomycosis generates a cytotoxic edema and in very advanced states ischemia of the compromised region and other irregularities of parenchyma surrounding the vessels simulating arteritis.

In conclusion, coccidioidomycosis, a rare disease in our country, has to be diagnosis to be considered in our region. In countries with the highest prevalence, where the desert regions present greater extensions, being a difficult diagnosis disease, should always be contemplated in the differential diagnoses, since although the clinic guides the clinician towards a direct alteration of the central nervous system, the images and the laboratory results are the joint pillar of diagnosis.

## References

1. Yau AA (2016) Risk factors and epidemiology of coccidioidomycosis demonstrated by a case of spontaneous pulmonary rupture of cavitary coccidioidomycosis. Case Reports in Infectious Diseases 6: 1-4.

2. Tortorano AM, Carminati G, Tosoni A, Tintelnot K (2015) Primary cutaneous coccidioidomycosis in an Italian nun working in South America and review of published literature. *Mycopathologia* 180: 229–235.
3. Singh G, Patel T, Hu S (2015) Disseminated cutaneous coccidioidomycosis in a liver transplant patient. *JAAD Case Reports* 1: 225-226.
4. Di Caudo DJ (2006) Coccidioidomycosis: A review and update. *J Am Acad Dermatol* 55: 929-942.
5. Garcia SC, Salas Alanis JC, Flores MG, Gonzalez SE, Cabrera LV, et al. (2015) Coccidioidomycosis and the skin: a comprehensive review. *An Bras Dermatol* 5: 610-621.
6. Duggan PT, Deegan AP, McDonnell TJ (2016) Case of coccidioidomycosis in Ireland. *BMJ Case Rep*.
7. Carrasco-Zuber JE, Navarette-Decenth C, Bonifaz A, Fich F, Vial-Letelier V, et al. Skin affection in deep mycoses: a review of the literature. Part II. Systemic mycoses. *Actas Dermosifiliogr* 10: 806-815.