

Medical Image

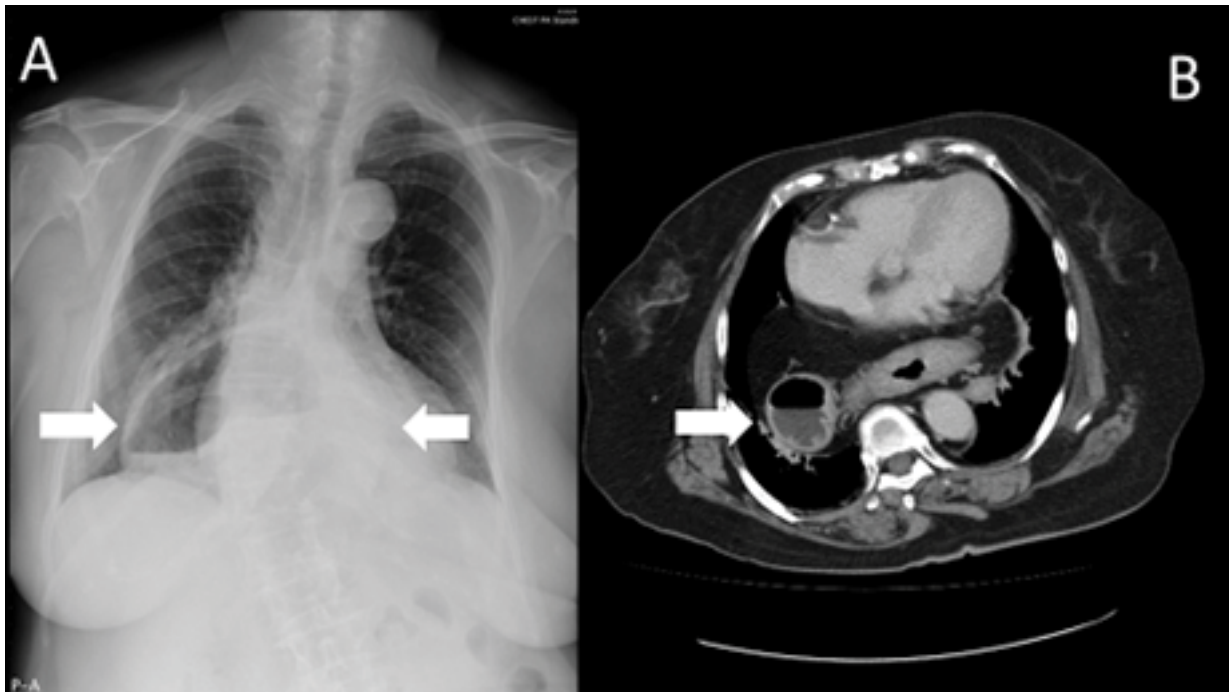
Title: A Retrocardiac Gas-filled Mass – Hiatal Hernia

Chia-Sheng Wang¹ and Wei-Ting Lin^{2,3*}

¹Department of Surgery, Chi Mei Medical Center, Liouying, Tainan, Taiwan

²Department of Orthopaedics, Chi Mei Medical Center, Tainan, Taiwan

³Department of Physical Therapy, Shu Zen College of Medicine and Management, Taiwan



An 85-year-old woman presented with retrosternal heartburn sensation and epigastric pain for months. Chest radiography showed a well-defined gas-filled opacity (Figure 1A, arrows). Computed tomography of chest revealed a retrocardiac mass with air-fluid level (Figure 1B). In addition, herniation of omentum through the esophageal hiatus with an increasing fat surrounding the lower esophagus was noted. Therefore, the diagnosis of hiatal hernia was confirmed.