

Clinical-Medical Image

Title: Alkali Chemical Burn with Placement of Morgan Lens

William Ensor^{1*}, Rahul Verma² and Ceylan Cankurtaran²

¹Philadelphia College of Osteopathic Medicine, 4170 City Ave Philadelphia, PA, USA

²Department of Neuroradiology, Einstein Medical Center, 5501 Old York Road Philadelphia, PA, USA

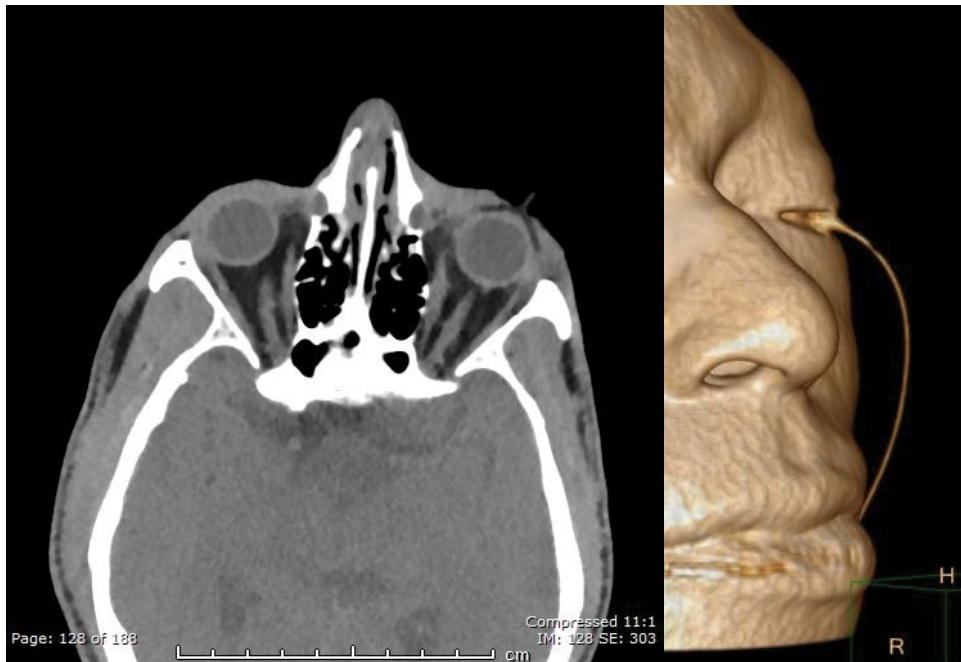


Figure 1: Axial computed tomography image (soft tissue window).

Figure 2: Computed tomography 3D reconstruction observing Morgan lens over the left globe.

A 50 year old African American male with no past medical history presented to the Emergency Department status post assault. History revealed use of a bleach-containing cleaning solution splashed in his face during assault. Physical exam was positive for a strong smell of bleach. Ophthalmic exam revealed bilateral periorbital edema as well as chemosis and conjunctival injection of the left eye. His visual acuity was 20/70 OD and 20/100 OS. The patient was diagnosed with an alkali chemical burn of the left eye and irrigation was initiated with placement of a Morgan Lens. Due to other injuries, Computed Tomography Imaging of the brain was performed. The findings are displayed in the Figures 1 and 2. There were no acute intracranial abnormalities or other orbital pathologic findings. Reconstructive 3D imaging of the CT scan was performed outlining placement of Morgan Lens.

*Corresponding author: William Ensor, Philadelphia College of Osteopathic Medicine, 4170 City Ave Philadelphia, PA, Tel: 610-842-2775; E-mail: Williamen@pcom.edu

Copyright: © 2016 Ensor W, et al. This is an open-access article distributed under the terms of the Creative Commons Attribution License, which permits unrestricted use, distribution, and reproduction in any medium, provided the original author and source are credited.