

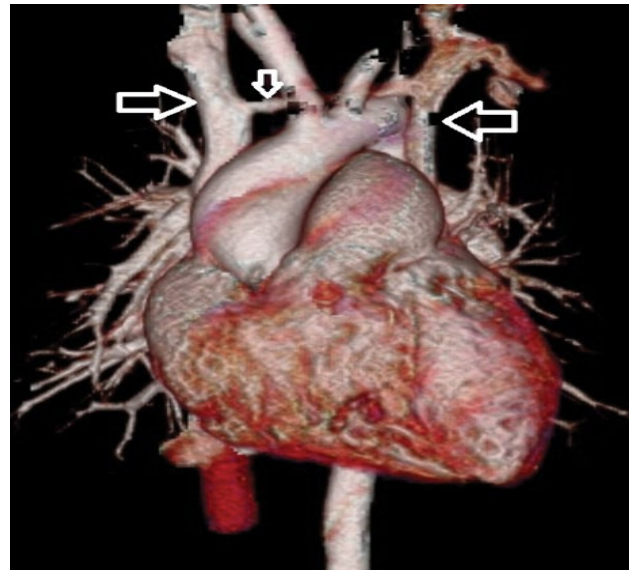
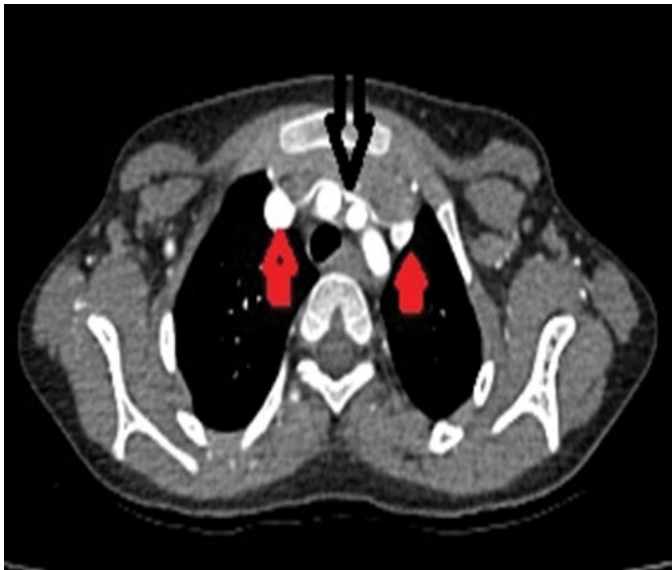
## Clinical Image

### Title: Double Superior Vena Cava

Suvendu Mohapatra<sup>1\*</sup>, and Rashmita Nayak<sup>2</sup>

<sup>1</sup>Department of Radiology S.C.B Medical College, India

<sup>2</sup>Department of Paediatrics S.C.B Medical College, India



Consent: Written informed consent was obtained from the parents of the patient for publication of this images.

Conflict of interest: The author(s) declare that they have no competing interests.

Figure 1: Eight Year Old Female Child with Progressive Dyspnoea for Last Couple of Days. On Echocardiography there is Pulmonary Trunk Prominence. Patient was sent for Ct Angiography which Revealed Persistent Left Superior Vena Cava with Horizontal Inter Communication with Right Side Superior Vena Cava. Axial CECT Image Reveal Two Superior Vena Cava (Marked Red Arrow) and the Intercommunicating Vein (Marked Black Arrow).

Figure 2: 3D Ct Angiographic Image Reveal Double Superior Vena Cava (Marked Horizontal Arrow) with the Venous Inter Communication (Marked Vertical Arrow).