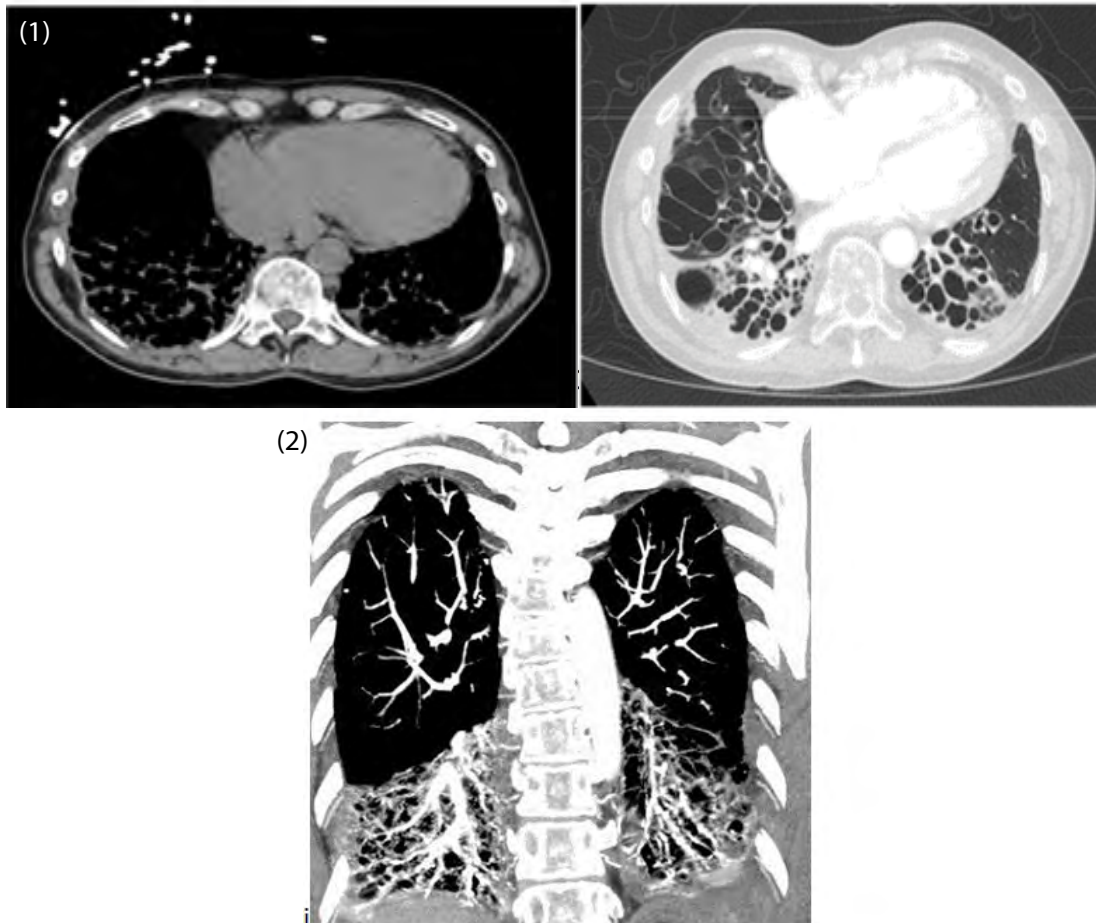


Clinical Image

## Lung Disease in Primary Ciliary Dyskinesia

Sameera Syed\* and Kanwal Farooq

Department of Internal Medicine, Raritan Bay Medical Center, Perth Amboy, New Jersey, USA



Figures 1: Cystic bronchodilatation.

Figure 2: Bronchiectasis involving lower lobes.

### Clinical Image

This is a 56 year old male with history of Primary Ciliary Dyskinesia (PCD) presented with hypoxia and cough with mucopurulent sputum. Since past 34 years patient has been troubled by recurrent severe lung infections requiring multiple hospital admissions. PCD is characterized by obstructive pattern of lung disease. The images depict classic cystic bronchodilatation (Figure 1) with bronchiectasis predominantly affecting lower lung lobes (Figure 2). The mainstays of treatment are airway clearance and aggressive antibiotic therapy. PCD is a rare ciliopathic autosomal recessive genetic disorder that causes defects in action of cilia lining the respiratory tract, fallopian tubes, as well as the flagella of sperm cells. The prevalence of PCD is about 1:10,000. Severe lung infections by virulent bacteria are the main cause of morbidity and mortality in these patients. Lung transplant is the only curative treatment in these patients.

\*Corresponding author: Sameera Syed, Department of Internal Medicine, Raritan Bay Medical Center, Perth Amboy, 08859, New Jersey, USA, Tel: 732-324-5080; E-mail: [sameera.syed@hackensackmeridian.org](mailto:sameera.syed@hackensackmeridian.org)

Citation: Syed S, Farooq K (2018) Lung Disease in Primary Ciliary Dyskinesia. *Int J Clin Med Imaging* 4: 602. doi:10.4172/2376-0249.1000602

Copyright: © 2018 Syed S, et al. This is an open-access article distributed under the terms of the Creative Commons Attribution License, which permits unrestricted use, distribution, and reproduction in any medium, provided the original author and source are credited.