

Case Blog

Title: Management of Tracheostomy Site Myiasis

Rajarshi S, Ajay M*, Jyoti RD, SiSwati S, Jayanta S and Basu SK

Department of ENT and Head Neck Surgery, RG Kar Medical College and Hospital, Kolkata, India

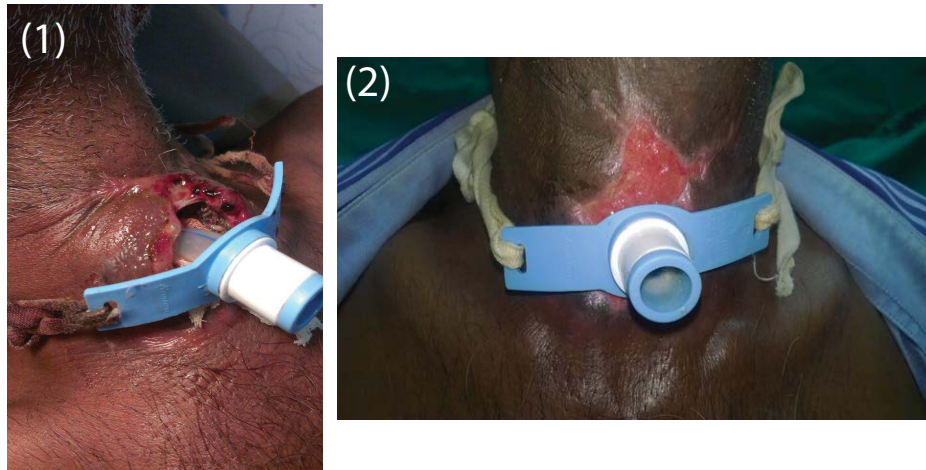
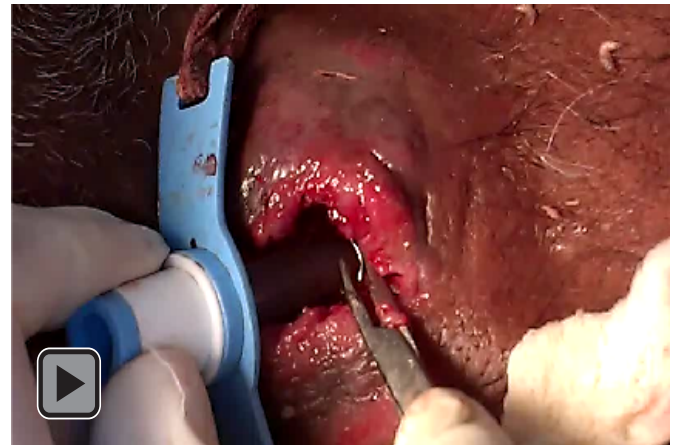
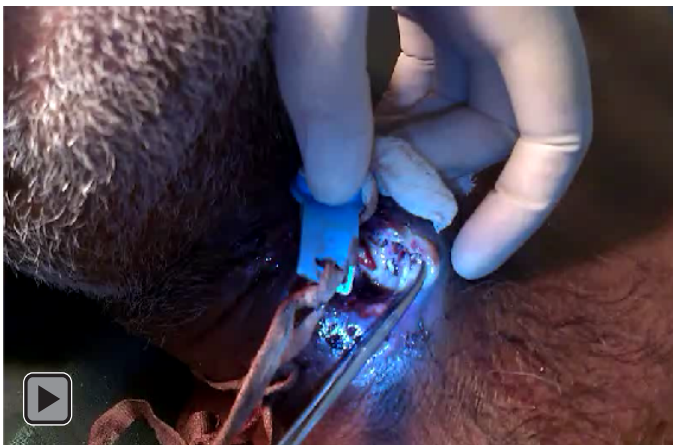

Figure 1: Tracheostomy wound site Myiasis.

Figure 2: On the day of discharge – healthy wound site.



Video 1: Live maggots.

Video 2: Removal of maggots.

Introduction

Myiasis, from the Greek myia for “fly,” has been defined as the infestation of live human or vertebrate animals with larvae of the insect order Diptera (flies), which feed on living or necrotic tissue [1]. Myiasis can also be classified according to the site of infestation. Cutaneous myiasis involves the invasion of the skin, with the most common target being a wound, near which an

*Corresponding author: Ajay M, Department of ENT, RG Kar Medical College, Kolkata, India, Tel: 033-2555-7656; E-mail: ajaymanickam87@gmail.com

Copyright: © 2015 Rajarshi et al. This is an open-access article distributed under the terms of the Creative Commons Attribution License, which permits unrestricted use, distribution, and reproduction in any medium, provided the original author and source are credited.

obligatory or facultative parasitic fly will lay eggs [1,2]. In “wound myiasis,” both healthy and necrotic tissues can be fed on by the larvae, depending on the conditions and species of fly involved. Apart from the skin, the eyes, ears, nose, and sinuses represent relatively common sites of attack whereas less common sites are the mouth, throat, urogenital, and gastrointestinal tracts [1,2]. We present a case with tracheostomy wound myiasis and detailed description of its management.

Case Blog

A 62 year male patient presented with respiratory distress at ENT emergency. On indirect laryngoscopy a supraglottic mass was seen. The patient underwent emergency tracheostomy. A 7.5 mm cuffed tracheostomy tube was inserted. Biopsy was taken from the supraglottic growth under direct laryngoscopic view. Histopathologic report was well differentiated squamous cell cancer. The tracheostomy tube was changed to uncuffed tube and the patient was discharged following referral to radiotherapy department. The importance of proper tracheostomy tube care was well explained to the patient and his relatives. The patient was irregular during followup period and presented to ENT opd after 3 weeks with complaints of itching sensation at the tracheostomy wound site. On examination maggots were seen in the tracheostomy wound (Figures 1 and 2).

Management of Tracheostomy Wound Myiasis

STEP 1: The wound site was cleaned carefully using 10% povidone iodine solution. Flushing was not done as uncuffed tracheostomy tube could not be changed to cuff due to chance of aspiration of infiltrating maggots surrounding the tracheostomy tube.

STEP 2: The tracheostomy tube was wrapped using normal saline soaked sterile gauze piece to prevent maggot movement towards trachea thus reducing chance of maggot aspiration.

STEP 3: Careful application of turpentine oil was done. The turpentine oil created an anaerobic atmosphere forcing the maggots to crawl towards the skin.

STEP 4: The maggots were removed using non toothed forceps carefully. The maggots were placed in bowl containing ether solution (Videos 1 and 2).

STEP 5: The tracheostomy wound was covered with povidone iodine soaked gauze piece.

The patient was admitted, inj. coamoxyclav and inj. metronidazole was started. Regular dressing was done maintaining the above mentioned 5 steps. The patient was discharged after 10 days with counselling regarding importance of proper and regular tracheostomy tube care.

Discussion

People living in underdeveloped countries where malnutrition and unsanitary condition are more prone, are vulnerable to disease such as myiasis [3]. Myiasis is the disease caused by invasion of organs and tissue by dipterous larvae, which last for a period of time and feed on the living or dead tissues. The larvae become mature and invasive and leave the necrotic tissue for viable tissue, causing extension of the lesion by local tissue destruction. One of the risk factor for the development of oral myiasis is poor hygiene. Myiasis is also found among elderly and abandoned individuals, as well as in interns of geriatric hospitals and mental institutions presenting poor hygiene habits [4].

The eggs are deposited by the female flies over the unbroken suppurating lesions or open wounds. Upon hatching, the maggots penetrate deep into tissue aided by their sharp mouth hooks and anchoring intersegmental spines and cause necrosis of the tissue. Progressive necrosis of the tissue continues, along with the deep invasion of the larvae until a cavernous lesion is formed, while the larvae aggregate and remain active. The lesion is characterized by tense and oedematous surrounding tissue with pungent odour. Extension of the lesion into body cavity would be seen in some of the cases.

The larvae can damage the vital tissues which sometime be fatal if they cause life threatening hemorrhage [5]. The severity of the lesion depends on the time interval from the onset of infection and the diagnosis of the lesion. If the lesion is diagnosed early, less number of larvae will be present with minimal tissue damage. But if the lesion is presented at later stage or delayed, it will result in greater number of larvae with extensive tissue necrosis. Therefore early diagnosis is crucial to limit tissue damage. Depending on the number of viable eggs that are actually deposited by the female fly, the same number of larvae hatches and grow in any lesion.

Mechanical removal of the larvae is the traditional treatment of myiasis [6]. Anti-larval measures includes use of turpentine oil or mixture of turpentine oil and chloroform followed by removal of the larvae [7]. But also use of topical and systemic antibiotic

as adjuvants in the treatment improves the favorability of prognosis in severe cases.

In this case emergency tracheostomy, early discharge and irregular follow up visits lead to myiasis of the tracheostomy wound. Regular sterile dressing, proper nutrition, and through understanding of the importance of wound management by the patient and patient party could have avoided this condition.

Conclusion

Myiasis can be prevented by practicing good personal hygiene, primary care of wound, controlling fly population and maintenance of sanitation of the surroundings. Apart from these, patient's relatives should be educated about the post-operative care, by teaching them the dressing and wound care and the importance of it, so that such manifestation of larvae could be prevented. Any symptoms relating to infestation should be reported to the hospital as the earliest, so that the lesion can be treated with minimal tissue damage rather than extensive necrosis when presenting at later stage. Myiasis can be prevented, so "prevention is better than cure".

References

1. Hall MJW, Smith KGV (1993) Diptera causing myiasis in man. In: Lane RP, Crosskey RW (eds) *Medical Insects and Arachnids*. London, Chapman and Hall 429-469.
2. James MT: The flies that cause myiasis in man. United States Department of Agriculture. Miscellaneous publication no: 631-1947
3. Auluck A (2005) Oralhealth of poor people in rural areas of developing countries. *J Can Dent Assoc* Nov: 71: 753-755
4. FAQ Ribeiro, Pereira CSB, Alves A, Marcon MA (2001) Treatment of human myiasis with ivermectin oral cavity. *Rev Bras Otorrinolaringol* 67: 755-761
5. Shinohara EH, Marini MZ, Oliveira Neto HG, Takahashi A (2004) Oral myiasis treated with ivermectin: case report. *Braz Dent J* 15, 79-81
6. Bhatt AP, Jayakrishnan A (2000) Oral myiasis: a case report. *Int J Paediatr Dent* 10, 67-70
7. Singh I, Gathwala G, Yadav SP, Wig U (1991) Ocular myiasis. *Indian Pediatr*: 28:152-155