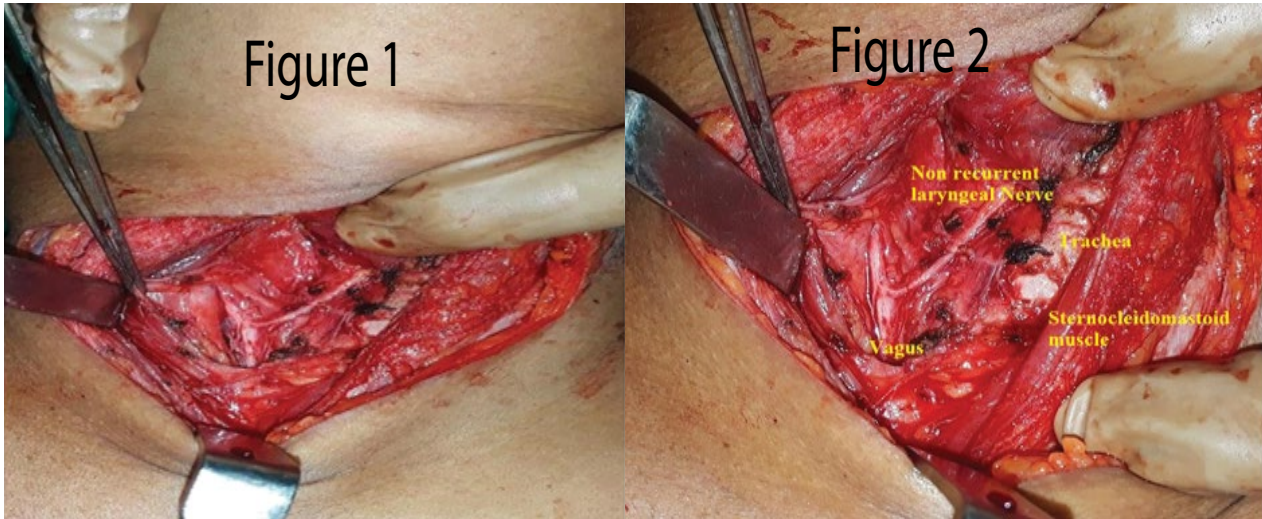


Clinical Image

## Non Recurrent Laryngeal Nerve – Still a Surprise

Bollineni Naren\*

Andhra Medical College, Andhra Pradesh, India



**Figure 1:** Non-recurrent Laryngeal Nerve

**Figure 2:** Non-recurrent laryngeal nerve in a case of carcinoma thyroid identified intraoperative while performing total thyroidectomy

### Clinical Image

Non Recurrent laryngeal is an incidental finding in surgeries for thyroid disorders. Incidence is somewhere around 0.3 to 0.5%. We found a case of right non-recurrent laryngeal nerve in a case of carcinoma thyroid operated for total thyroidectomy (Figure 1 and Figure 2).

\*Corresponding author: Bollineni Naren, Andhra Medical College, Andhra Pradesh, India; E-mail: [bollineni.naren@gmail.com](mailto:bollineni.naren@gmail.com)

Citation: Naren B (2018) Non Recurrent Laryngeal Nerve-Still a Surprise. *Int J Clin Med Imaging* 5: 610. doi:10.4172/2376-0249.1000610

Copyright: © 2018 Naren B. This is an open-access article distributed under the terms of the Creative Commons Attribution License, which permits unrestricted use, distribution, and reproduction in any medium, provided the original author and source are credited.