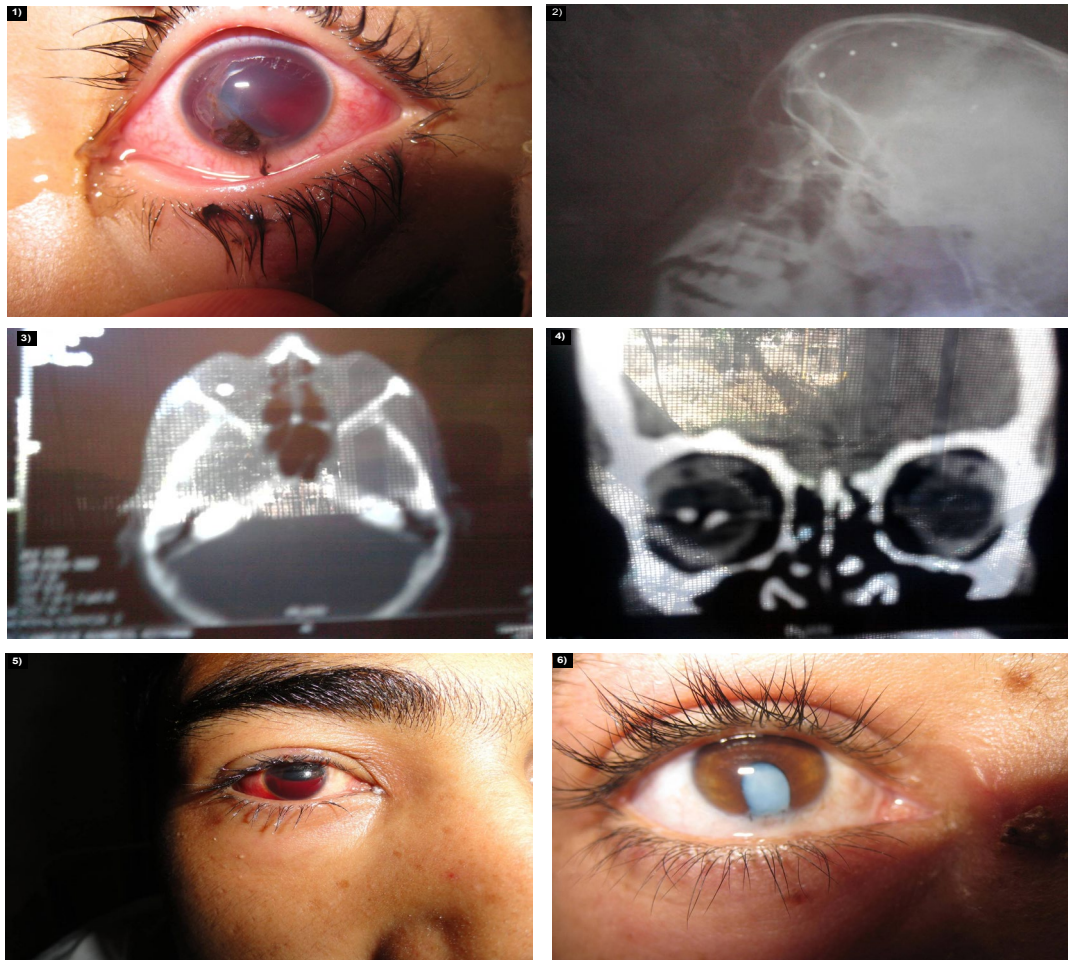


Clinical Image

Title: Pellet Gun Injury

Pervaiz Majeed Zunga*¹ and Obaid Majid¹

Registrar Internal Medicine, SMHS Hospital Govt. Medical College, Srinagar, India



The case was observed in a series of patients who was hospitalized with pellet gun injury in the different consequences. Each figure depicts different subjects of cases with similar symptoms of hyphaema.

Figure 1: The above patient was a young boy 12 years old male. The picture depicting hyphaema with pellet entry wound.

Figure 2: Again another boy with multiple pellet foreign bodies in orbit and skull

Figure 3: CT SCAN depicting pellet foreign body in left globe

Figure 4: Multiple Pellet foreign bodies in right eye

Figure 5: Again young male with hyphaema due to pellet gun injury

Figure 6: Young male with pellet injury and inferior iridodialysis