

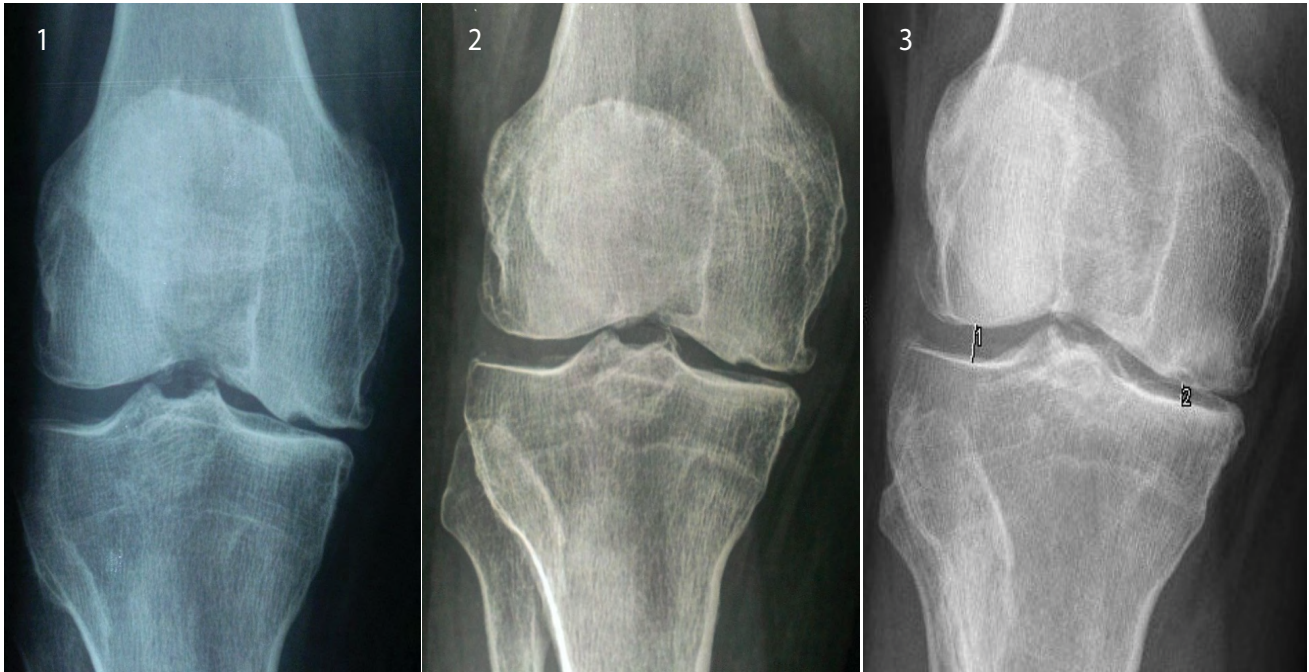
Clinical Image

Effectiveness of Ozone in Osteoarthritis of the Knee

Marcos Edgar Fernández-Cuadros^{1*} and Olga Susana Pérez-Moro²

¹Department of Rehabilitation and Physical Medicine, Santa Cristina's University Hospital, Madrid and Santísima Trinidad Foundation's Hospital, Spain

²Department of Rehabilitation and Physical Medicine, Santa Cristina's University Hospital, Madrid, Spain



Figures 1-3: Severe knee osteoarthritis.

Keywords: Knee pain; osteoarthritis; ozone

Osteoarthritis (OA) is a degenerative disease that is very prevalent, and it usually increases exponentially with age [1]. OA affects weight bearing articulations as the knee, and is very common in women [1]. Knee OA affects negatively the function and autonomy of older people [2], decreasing patient's quality of life [3]. OA produces a great use of limited health resources [3]. The normal knee is composed by cartilage, subchondral bone, synovial tissue and articular capsule. Knee OA produces destruction of articular cartilage and sclerosis of subchondral bone [2]. Knee OA diminishes the articular space, and it favours the formation of osteophyte and subchondral cysts [2]. To date, there is neither effective treatment nor cure for OA. The objectives on treating Knee OA are to ameliorate pain, rigidity, inflammation and to avoid articular damage and joint destruction [2].

Recently, OA is related to chronic inflammation, besides mechanical and biological factors. In that scenario, future OA treatments must regulate inflammation to avoid OA progression. Fernández-Cuadros et al state that Ozone acts on the modulation of inflammation [2], based on several studies and years of clinical experience. It is believed that Ozone acts on the articulation as a stimulator, repairing the fibroblastic tissue. Moreover, Ozone could reduce inflammation and promote growth of new cartilage [2].

We present the case of an 83 years-old female, with Kellgren-Lawrence 3rd degree, and with joint narrowing space and subchondral cyst, and moderate-severe pain on the knee. After a two series of ozone therapy (20 cc of a mixture of Oxygen-Ozone 95-5%, at 20 ug concentration, 4 weekly sessions) separated by six months, the recovering of the joint space and of the subchondral cyst and a decrease in pain is been observed (Figures 1-3).

This case report and many years of experience demonstrate that Ozone is capable of diminishing pain and inflammation. Ozone acts on the repair of articular cartilage and subchondral bone, because it increases vascularisation of the articular cartilage [2].

**Corresponding author:* Marcos Edgar Fernández-Cuadros, Department of Rehabilitation and Physical Medicine, Santa Cristina's University Hospital, Madrid and Santísima Trinidad Foundation's Hospital, Spain, Tel: 0034620314558; E-mail: marcosefc@hotmail.com

Citation: Fernández-Cuadros ME, Pérez-Moro OS (2016) Effectiveness of Ozone in Osteoarthritis of the Knee. *Int J Clin Med Imaging* 3: 509. doi: [10.4172/2376-0249.1000509](https://doi.org/10.4172/2376-0249.1000509)

Copyright: © 2016 Fernández-Cuadros ME, et al. This is an open-access article distributed under the terms of the Creative Commons Attribution License, which permits unrestricted use, distribution, and reproduction in any medium, provided the original author and source are credited.

References

1. Fernández Cuadros ME, Pérez-Moro OS, Mirón-Canelo JA (2016) Knee Osteoarthritis: Impact on Quality of Life and effectiveness of Total Knee Arthroplasty. *Divers Equal Health Care* 13: 278-283.
2. Fernández Cuadros ME, Pérez-Moro OS, Mirón-Canelo JA (2016) Could Ozone be used as a Feasible Future Treatment in Osteoarthritis of the Knee? *Divers Equal Health Care* 13: 232-239.
3. Fernández-Cuadros ME (2013) Análisis de la calidad de vida en pacientes con prótesis total de rodilla. Tesis Doctoral. Universidad de Salamanca. España.