

Clinical-Medical Image

Liver Scalping: A Suggestive Sign of Pseudomyxoma Peritonei

Sanae Amalik, Kaoutar Imrani, Hind Sahli, Hounayda Jerguigue, Rachida Latib and Youssef Omor

Department of Radiology, Oncology National Institute, Rabat, Morocco

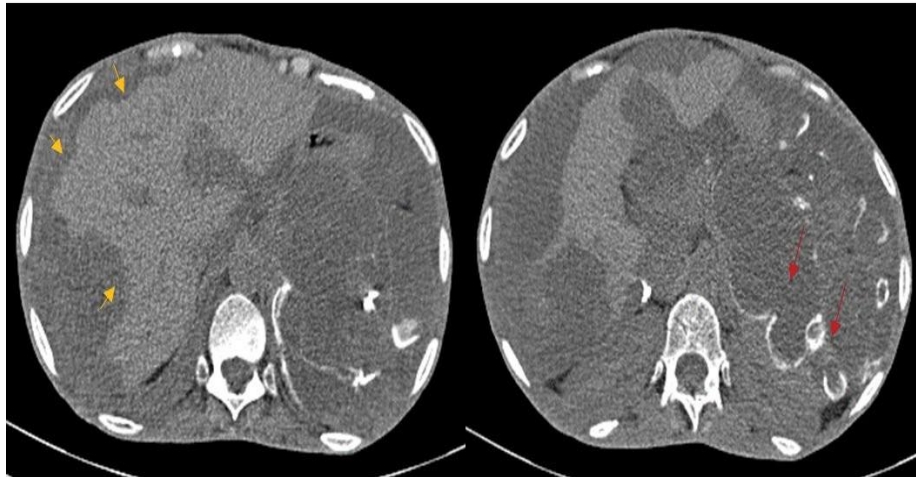


Figure 1 : Axial abdominal CT on portal venous phase in a 45 year-old woman followed for mucinous neoplasm of the appendix showing pseudomyxoma peritonei, presenting as low attenuation ascites causing scalloping of liver surfaces (yellow arrow). Associated curvilinear calcifications are seen (red arrow).

Clinical Image

Pseudomyxoma Peritonei (PMP) is an uncommon disease characterized by bulky accumulation of mucinous tumor deposits in the peritoneal cavity. It is a rare tumor with an incidence of one to two per million per year, affecting mostly middle-aged women of 53 years of age. Mucinous neoplasms of the appendix are the most common primary tumors associated with PMP. Its symptomatology is non-specific and may include an increase in abdominal size, inguinal hernia in men and ovarian mass in women. Diagnosis is guided by CT scan, which allows the identification of loculated mucinous ascites (Figure 1), which accumulate along peritoneal surfaces producing a characteristic mass effect on the liver and spleen, producing a scalloped appearance, with multiple areas of peritoneal nodularity and thick omental caking. Curvilinear calcifications may be present and helps differentiate pseudomyxoma from peritoneal carcinomatosis. An appendiceal mucocele may be visualized. Treatment is based on cytoreduction surgery and perioperative intraperitoneal chemotherapy.

Keywords: Pseudomyxoma peritonei; Scalping; CT

Declaration of Interests

The authors declare that they have no competing interests.

***Corresponding author:** Amalik S, Department of Radiology, Oncology National Institute, Rabat, Morocco, Tel: +212672257226; E-mail: sanaeamalik@gmail.com

Citation: Amalik S, Imrani K, Sahli H, Jerguigue H, Latib R, et al. (2021) Liver Scalping: A Suggestive Sign of Pseudomyxoma Peritonei. *Int J Clin Med Imaging* 8:758.

Copyright: © 2021 Amalik S, et al. This is an open-access article distributed under the terms of the Creative Commons Attribution License, which permits unrestricted use, distribution, and reproduction in any medium, provided the original author and source are credited.
