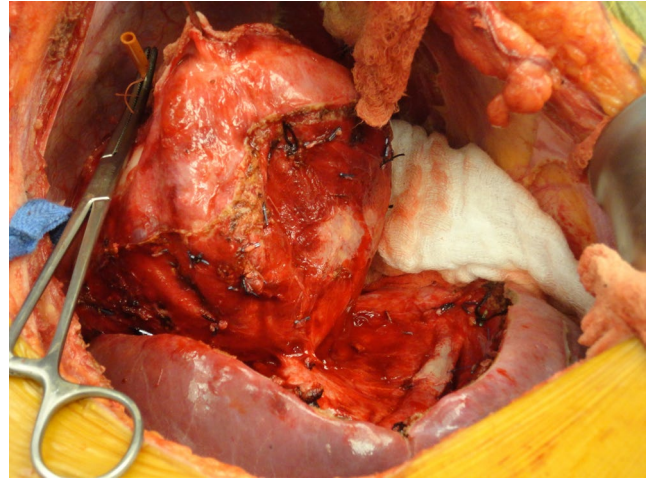
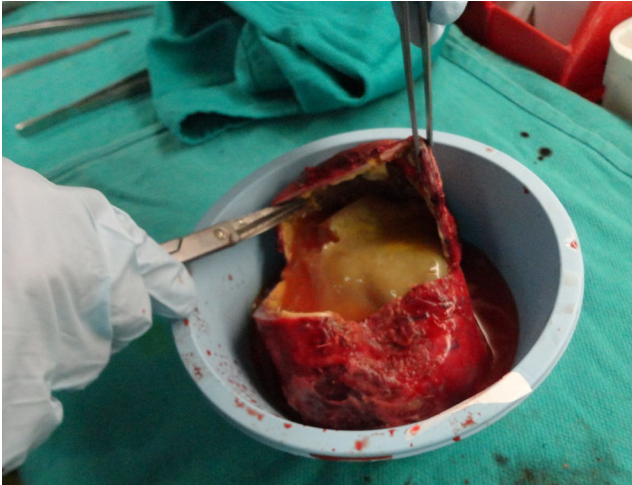

Clinical Image

Title: Echinococcal Liver Cyst

Jennifer A. Berumen^{1*}, Daniel Campos¹, Elyssa Feinberg¹ and Marc L. Melcher¹

Department of Abdominal Transplant, Stanford University, USA



These are intraoperative images of a 25 year old woman presenting with abdominal pain and early satiety. A CT scan suggested the presence of an echinococcal cyst. After being treated with albendazole, the patient was taken to the operating room where the cyst was exposed and infused with hypertonic saline through a rubber catheter. Care was taken to avoid spillage of cyst contents. Cyst was opened on the back table to reveal a thick gel-like material.

*Corresponding author: Jennifer A. Berumen, Department of Abdominal Transplant, Stanford University, Palo Alto, CA 94304, USA, Tel: (650) 498-5689; Fax: (650) 498-5690; E-Mail: jberumen@stanford.edu

Copyright: © 2014 Berumen J A. This is an open-access article distributed under the terms of the Creative Commons Attribution License, which permits unrestricted use, distribution, and reproduction in any medium, provided the original author and source are credited.