

Case Blog

Title: Esophageal Web in a Child

Altamimi E*

Department of Pediatrics, Faculty of Medicine, Mu'tah University, Alkarak, 61710, Jordan

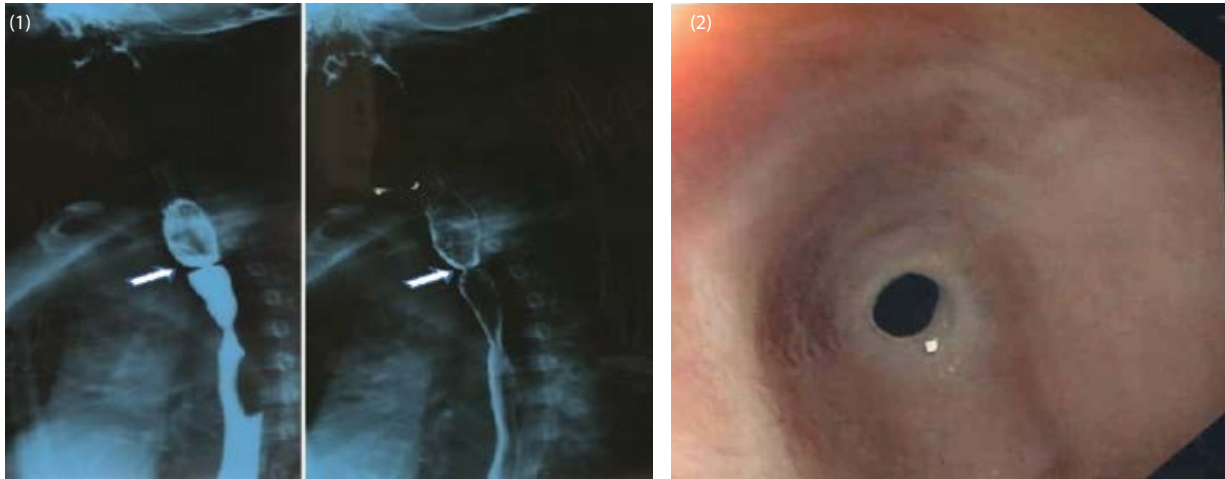


Figure 1: Barium esophagram demonstrated a thin membrane arising at cervical esophagus with circumferential involvement of the lumen, characteristic of an esophageal web.

Figure 2: Esophagoscopy showed a ring-like narrowing of the cervical esophagus and normal-looking mucosa around the narrowing.

An 11-year-old boy presented with a history of dysphagia and food sticking of 1-year duration. He had occasional vomiting. The child denied any epigastric pain, heart burn, choking, or respiratory symptoms, and had no history of atopy or anemia symptoms. Symptoms improved with drinking water. His growth parameters were in the fifth percentile for his age. He showed no signs of anemia and a benign abdominal exam. His laboratory workup showed normal Complete Blood Count, liver enzymes and allergy panel. His barium esophagram demonstrated an esophageal web (Figure 1). An Esophagoscopy showed a ring-like narrowing of the cervical esophagus; the scope could not be passed through the narrowing, with normal looking mucosa around (Figure 2).

An esophageal web is a ring-like constriction of the upper esophagus covered on the superior and inferior surfaces by squamous epithelium [1]. The most common cause is idiopathic. It can be associated with other disorders, such as Plummer-Vinson Syndrome, GVHD, and epidermolysis bullosa [1]. Although esophageal webs can be an accidental finding, and many of them are ruptured during endoscopy, esophageal dilatation (balloon/bougienage) may be needed [2]. Unfortunately, the parents refused any intervention beyond endoscopy, as they felt his symptoms were improving.

References

1. Michael S. Smith (2010) Diagnosis and Management of Esophageal Rings and Webs. *Gastroenterol Hepatol (NY)* 6: 701-704.
2. Lindgren S (1991) Endoscopic dilatation and surgical myectomy of symptomatic cervical esophageal webs. *Dysphagia*. 6: 235-238.